



©2015 Dustri-Verlag Dr. K. Feistle  
ISSN 0722-5091

DOI 10.5414/NP300779  
e-pub: September 10, 2014

## Elevated numbers of mast cells in angiomatous meningioma

Bartosz Bujan<sup>1,2</sup> and Hans D. Mennel<sup>1</sup>

<sup>1</sup>*Department of Neuropathology,  
University of Marburg, Marburg, and*

<sup>2</sup>*Department of Neurology,  
Rehabilitation MediClin Center Bad Orb,  
Bad Orb, Germany*

Sir, – Angiomatous meningioma is a subgroup of meningioma with an extraordinary number of vessels. The diagnosis “meningioma, angiomatous,” however, is hampered by the fact that the different components of this tumor entity are not clearly specified, especially in terms of their quantitative relations. In the last draft of the WHO classification, the following description of the tumors is given: “Angiomatous meningioma exhibits numerous blood vessel on the background of a typical meningioma” [1, 2]. Therefore, to overcome this diagnostic difficulty, it has been postulated that the vascular component of the neoplasm should exceed 50% of the total tumor area [3].

Angiomatous meningiomas are frequently associated with pronounced edema [1, 4]. Angiomatous (and secretory) meningiomas show edema production in ~ 80% [5] of the cases compared to an unselected meningioma sample with only ~ 60% [4]. In previous studies it had been shown that secretory meningiomas are also strongly vascularized and exhibit high mast cell density, with obvious accumulation of mast cells around newly formed vessels [6, 7]. These similarities prompted us to analyze angiomatous meningiomas for their mast cells, density and edema formation. To corroborate our previous preliminary findings, we therefore studied anew the cohort of angiomatous meningiomas (n = 27) in comparison to unselected meningiomas (n = 16) and secretory meningiomas (n = 14). The aim of the study was to better understand the interaction of mast cells and vessel proliferation in the various subgroups with increased edema formation compared to “common” specimens of the meningioma variety. Furthermore, we tried

to determine whether the occurrence of mast cells could serve as a diagnostic criterion for angiomatous meningiomas.

The former morphology was characterized by extended fields of large vessels alternating with isomorphic tumor parts with endotheliomatous differentiation (Figure 1A). In contrast, tumors with microvascular features almost entirely consisted of densely arranged capillary vessels (Figure 1B). Few tumors, however, presented with architectural properties that showed some transition between both histological textures. There was no evidence whatsoever for malignant change in our cohort. Mast cells could be demonstrated by aniline dyes, especially when using the cresyl violet stain (Figure 1C arrows). This procedure obviously depicts some mast cells, but may fail to do so when the characteristic granula are absent or sparse.

Immunostaining for CD 34 yielded a reliable picture of the arrangement of vessels of various diameters, albeit of the macrovascular type (Figure 1D) or else of the presence of abundant small vessels in the microvascular subtype (Figure 1E). The immunoreaction or CD117 reliably detected mast cells, whether loaded with granula or almost depleted of them. Generally there was a considerable mast cells density in most angiomatous meningiomas (Figure 1H), and clusters of mast cells around vessels were frequently found (Figure 1G). The immunologically detected expression of EMA confirmed the typically strong reaction in the meningioma cell membranes (Figure 1F). Immunostaining for CKMNF did not reveal any epithelial differentiation. An electron microscopic examination performed in three cases of angiomatous meningiomas revealed normally structured capillaries without any evidence of pericyte proliferation.

Angiomatous meningiomas in our retrospective study contained a significantly higher percentage of mast cells than the unselected specimens ( $0.32\% \pm 0.48$  vs.  $0.13\% \pm 0.53$ ,  $p < 0.05$ ). In a previous study, we found a mast cell density of 0.23% in angiomatous meningioma; the corresponding values in an unselected meningioma group were 0.09%. These relations could in general be reproduced in our actual study by slightly changing values. The comparison with the pertinent percent

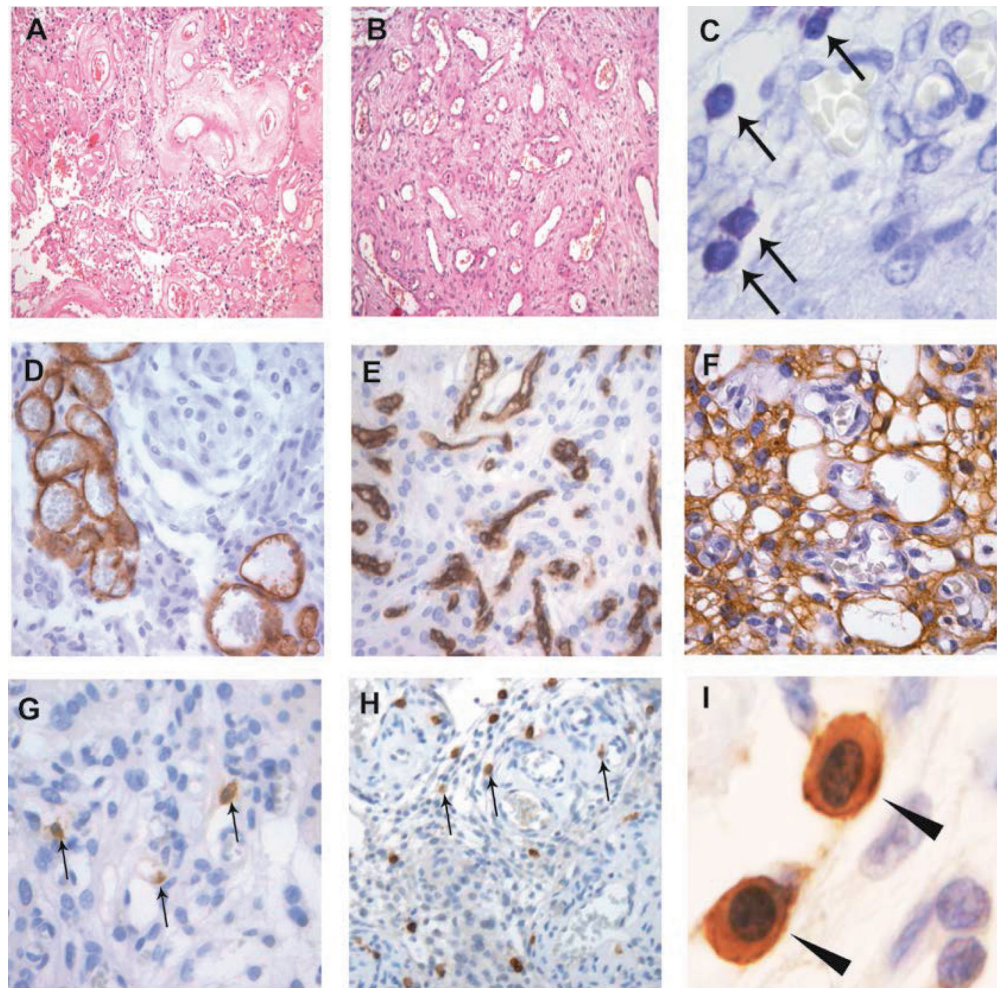


Figure 1. Microscopic findings: H & E staining showing parts of angiomatous meningioma with large vessels and syncytial-endotheliomatous background, macrovascular subtype (A); H & E staining showing parts of angiomatous meningioma with a pseudocystic architecture and abundant small vessels, microvascular subtype (B); staining for cresyl violet with mast cells (marked with arrows), magnification  $\times 400$  (C); immunostaining for CD34: absence of large vessels by macrovascular subtype (D) and abundant small vessels by microvascular subtype (E); immunostaining for EMA showing strongly membranous expression (F), arrows mark mast cells in immunostaining for CD117 occasionally clustered around vessels (G) and high proportion to tumor cells (H); arrowheads revealing mast cells with strong CD117 expression, higher magnification,  $\times 1,000$  (I).

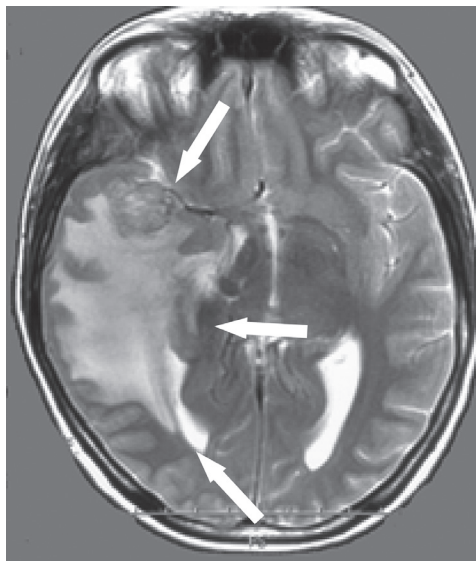


Figure 2. Axial view of T2-weighted MRI reveals a well-demarcated isotense temporal tumor with severe peritumoral edema (marked with arrows), graded with III in Steinhoff classification [7, 11].

in the secretory subgroup was 0.7% in the previous and 1.11% in the current investigation [7]. Thus, the general relations were preserved despite the slightly varying counting results (0.32% vs. 0.23%; 0.14% vs. 0.09% and 0.7% vs. 1.11%) [7].

Furthermore, clinical evidence points to increased risk of brain edema (Figure 2) for both, as was also documented in one of our angiomatous cases [7].

We suggest that future clinicopathologic studies should consider the occurrence of mast cells as a diagnostic criterion for angiomatous meningioma. Furthermore, a better understanding of the impact of mast cells upon edema formation could eventually contribute to the implementation of new drugs

Table 1. Mast cell density of meningiomas.

	Angiomatous meningiomas	Secretory meningiomas	Unselected meningiomas	
	n = 27	n = 14	n = 16	p
Age (mean age, $\pm$ SD) (y)	57.5 $\pm$ 18.1	57.6 $\pm$ 11.2	54.4 $\pm$ 21.6	NS
Sex (male : female)	8 : 19	3:11	7:9	NS
Mast cell density (%) (mean, $\pm$ SD, CI)	0.32 $\pm$ 0.48 (0.23 – 0.41)	1.11 $\pm$ 0.72 (0.83 – 1.39)	0.13 $\pm$ 0.24 (0.00 – 0.27)	p < 0.05*; p < 0.001*

$\pm$  SD = standard deviation; CI = confidence interval 95%; \*significant; NS = not significant.

to improve edema treatment by substances such as cromoglycan [8, 9]. Yet, mast cells, which are but one factor in tumorigenesis or progression, also contain several compounds that may act on tissue and/or cells [9]; thus, a rather general approach seems reasonable. We consider it fully justified, therefore, to rely upon histologic findings, as given in this publication, to better understand the intricate correlation of various tissue constituents, such as differing tumor compartments, vessels, connective tissue and the like, to continue or even simplify earlier often extensive subdivisions [10].

## Conflict of interest

None of the authors report any conflict of interest or financial disclosure.

## References

- [1] Louis DNCW, Ohgaki H. WHO Classification of Tumours of the Central Nervous System. Lyon, France: IARC Press; 2007.
- [2] Kleihues PCW. Tumours of the Nervous System. Lyon: World Health Organization IARC Press; 2000.
- [3] Hasselblatt M, Nolte KW, Paulus W. Angiomatous meningioma: a clinicopathologic study of 38 cases. *Am J Surg Pathol*. 2004; 28: 390-393. [CrossRef PubMed](#)
- [4] Bitzer M, Nägele T, Geist-Barth B, Klose U, Grönewäller E, Morgalla M, Heiss E, Voigt K. Role of hydrodynamic processes in the pathogenesis of peritumoral brain edema in meningiomas. *J Neurosurg*. 2000; 93: 594-604. [CrossRef PubMed](#)
- [5] Bitzer M, Wöckel L, Morgalla M, Keller C, Friese S, Heiss E, Meyermann R, Grote E, Voigt K. Peritumoural brain oedema in intracranial meningiomas: influence of tumour size, location and histology. *Acta Neurochir (Wien)*. 1997; 139: 1136-1142. [CrossRef PubMed](#)
- [6] Mennel HDM. R. Epithelial differentiation and vasculature in secretory meningiomas. Seventh Congress of the European Association for Neuro-Oncology (EANO). Vienna: Abstracts from the Seventh Congress of the European Association for Neuro-Oncology (EANO). *Neuro-oncol*. 2006; 8: 344.
- [7] Tirakotai W, Mennel HD, Celik I, Hellwig D, Bertalanffy H, Riegel T. Secretory meningioma: immunohistochemical findings and evaluation of mast cell infiltration. *Neurosurg Rev*. 2006; 29: 41-48. [CrossRef PubMed](#)
- [8] Bischoff SC. Role of mast cells in allergic and non-allergic immune responses: comparison of human and murine data. *Nat Rev Immunol*. 2007; 7: 93-104. [CrossRef PubMed](#)
- [9] Mattila OS, Strbian D, Saksi J, Pikkarainen TO, Rantanen V, Tatlisumak T, Lindsberg PJ. Cerebral mast cells mediate blood-brain barrier disruption in acute experimental ischemic stroke through perivascular gelatinase activation. *Stroke*. 2011; 42: 3600-3605. [CrossRef PubMed](#)
- [10] Cushing H, Eisenhardt L. Meningiomas: their classification, regional behaviour, life History, and surgical end results. Baltimore: Springfield; 1938.
- [11] Reszec J, Hermanowicz A, Rutkowski R, Bernaczyk P, Mariak Z, Chyczewski L. Evaluation of mast cells and hypoxia inducible factor-1 expression in meningiomas of various grades in correlation with peritumoral brain edema. *J Neurooncol*. 2013; 115: 119-125. [CrossRef PubMed](#)

Correspondence to:  
Bartosz Bujan, MD  
Department of Neurology,  
Rehabilitation MediClin Center Bad Orb,  
Spessartstraße 20,  
63619 Bad Orb, Germany  
bbujan@gmx.de