

Structure of Noses	Runny Noses	Noses Gone Bad	Congenital Nose Masses	Pictures of Noses	Nasal Grab Bag
\$100	\$100	\$100	\$100	\$100	\$100
\$200	\$200	\$200	\$200	\$200	\$200
\$300	\$300	\$300	\$300	\$300	\$300
\$400	\$400	\$400	\$400	\$400	\$400
\$500	\$500	\$500	\$500	\$500	\$500

FINAL JEOPARDY

**What sinuses are present at birth?**

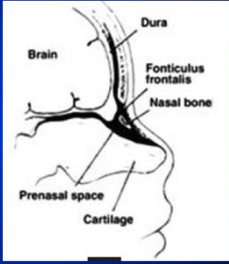
**Ethmoid  
Maxillary**

**When does the frontal and sphenoid sinuses achieve full adult size?**

**Late teenage years**

**What is the fontanelle between the inferior frontal and nasal bones?**

**Fronticulus nasofrontalis**



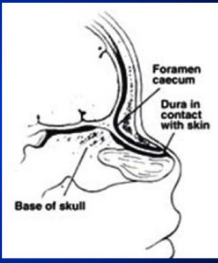
**JEPARODY** [Home] [Correct] [Wrong] [Cheer] [Boo] [Silence]

**What is the region between the ethmoid and frontal bones, which connects with the prenasal space?**

[Start Timer] [GO TO RESPONSE]

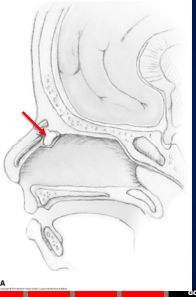
**JEPARODY** [Home] [Correct] [Wrong] [Cheer] [Boo] [Silence]

**Foramen cecum**



**JEPARODY** [Home] [Correct] [Wrong] [Cheer] [Boo] [Silence]

**Where does this sinus tract extend?**



[Start Timer] [GO TO RESPONSE]

**JEPARODY** [Home] [Correct] [Wrong] [Cheer] [Boo] [Silence]

**Prenasal space**







**JEPARODY** [Home] [Correct] [Wrong] [Cheer] [Boo] [Silence]

**What are two common pathogens in pediatric acute rhinosinusitis?**



[Start Timer] [GO TO RESPONSE]







**JEPARODY** [Home] [Correct] [Wrong] [Cheer] [Boo] [Silence]

**S. Aureus**  
**Streptococcus Pneumoniae**  
**Moraxella Catarrhalis**  
**Haemophilis influenzae**







JEPARODY      

**What are three diseases on the differential diagnosis for pediatric CRS?**



 







JEPARODY      

**Adenoid hypertrophy**  
**Cystic fibrosis (look for polyps)**  
**IgG subclass deficiencies/Immune deficiencies**  
**Asthma**  
**Gerd**  
**Allergies**  
**Recurrent viral URIs**







JEPARODY      

**Name 2 possible antibiotics in a child with acute sinusitis who has a b-lactam allergy**



 







JEPARODY      

**Bactrim**  
**Azithromycin**  
**Clarithromycin**  
**Erythromycin**

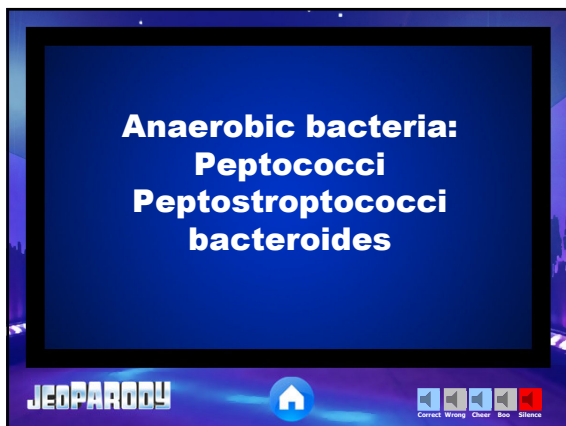
JEPARODY      

**What types of bacteria are found in pediatric chronic sinusitis more frequently than acute?**

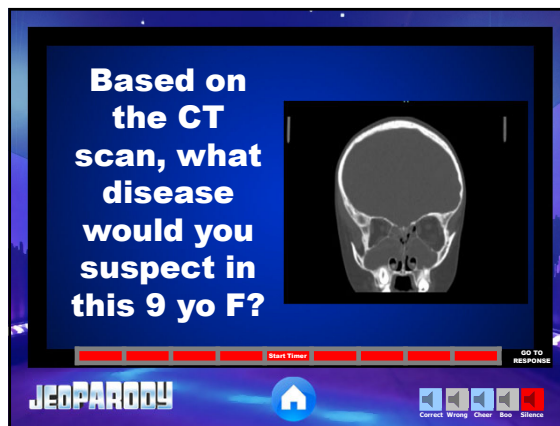

JEPARODY      

**Anaerobic bacteria:**  
**Peptococci**  
**Peptostreptococci**  
**bacteroides**



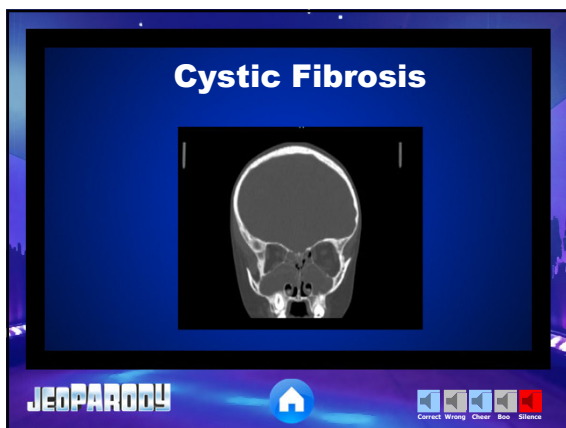

JEOPARDY! Start Timer GO TO RESPONSE Correct Wrong Cheer Boo Silence

**Based on the CT scan, what disease would you suspect in this 9 yo F?**



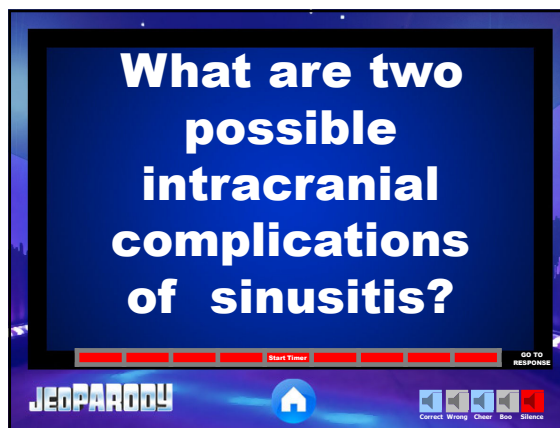
JEOPARDY! Start Timer GO TO RESPONSE Correct Wrong Cheer Boo Silence

**Cystic Fibrosis**



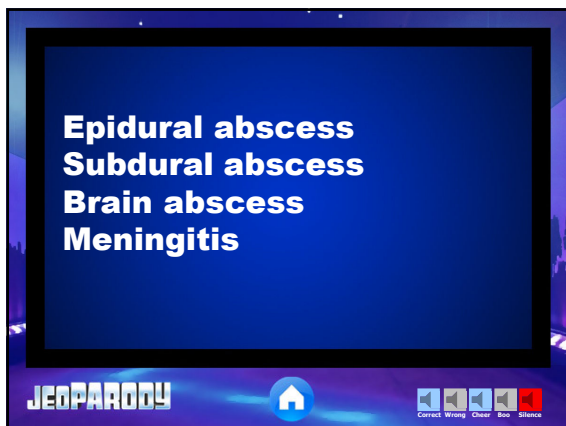
JEOPARDY! Start Timer GO TO RESPONSE Correct Wrong Cheer Boo Silence

**What are two possible intracranial complications of sinusitis?**



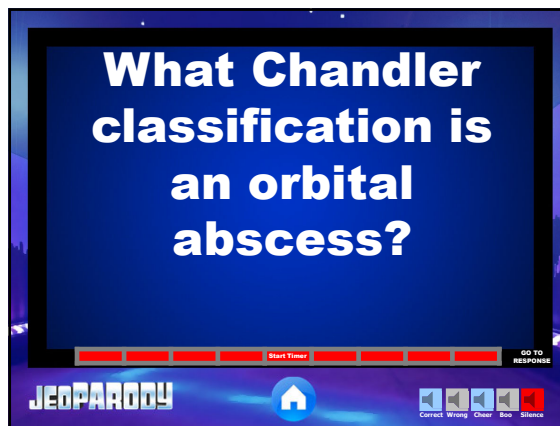
JEOPARDY! Start Timer GO TO RESPONSE Correct Wrong Cheer Boo Silence

**Epidural abscess**  
**Subdural abscess**  
**Brain abscess**  
**Meningitis**



JEOPARDY! Start Timer GO TO RESPONSE Correct Wrong Cheer Boo Silence

**What Chandler classification is an orbital abscess?**



JEOPARDY! Start Timer GO TO RESPONSE Correct Wrong Cheer Boo Silence

I. Preseptal cellulitis  
 II. Orbital cellulitis  
 III. Subperiosteal abscess  
 IV. Orbital abscess  
 V. Cavernous sinus thrombosis

**JEPARODY**

What is your diagnosis?

**JEPARODY**

Subperiosteal Abscess

**JEPARODY**

What is the Tobey Ayer/ Queckenstedt test?

**JEPARODY**

In cavernous sinus thrombosis, compression of the IJV on the thrombosed side causes no increase in ICP but compression on the nonaffected side causes increase in ICP







**JEPARODY**

What is your surgical approach?







From: Otolaryngology Prep and Practice

**JEPARODY**







**Any combination that drains intracranial, sinus and orbit (ie craniotomy + ESS + open/endoscopic subperiosteal drainage)**

JEPARODY      







**What is the most common congenital midline nasal mass?**

JEPARODY      







**Dermoid**

JEPARODY      

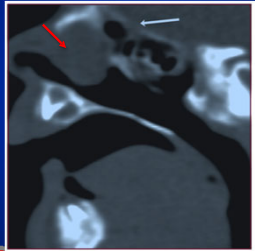
**What is a positive Furstenberg sign?**

JEPARODY      







**Increase in lesion size with straining, crying or dependent head position. Can distinguish encephaloceles from a glioma or dermoid**

JEPARODY      

**Name a congenital mass that is no longer on the differential?**

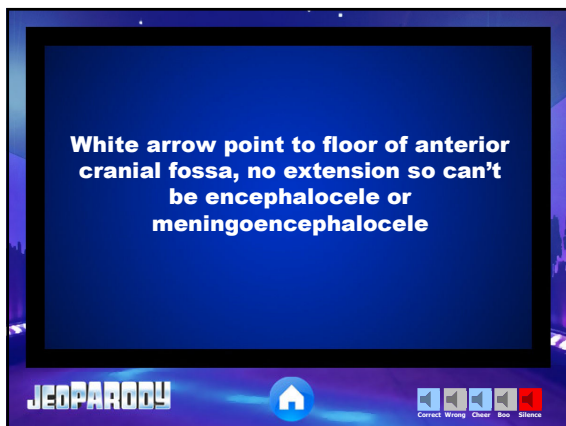


From: Otolaryngology Prep and Practice

JEPARODY      

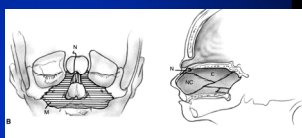
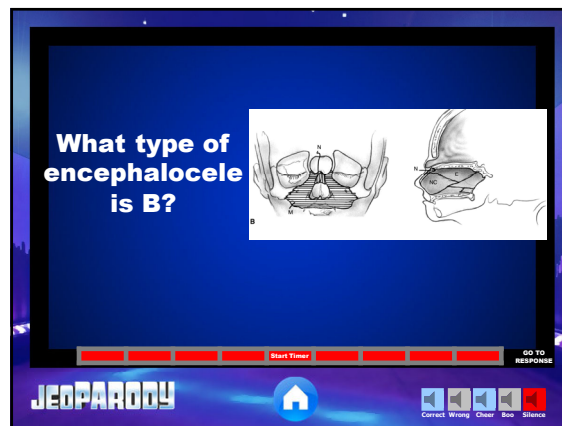


White arrow point to floor of anterior cranial fossa, no extension so can't be encephalocele or meningoencephalocele



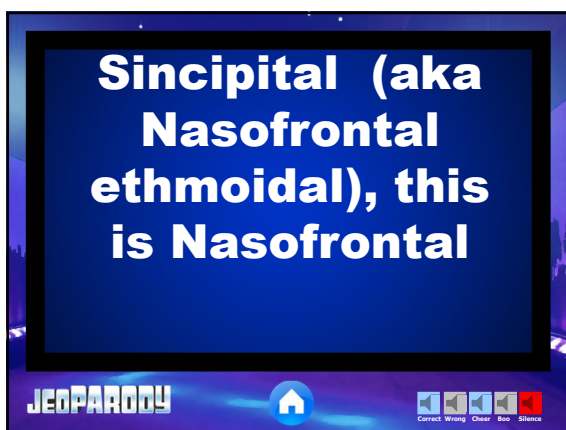
**JEOPARDY!** Start Timer GO TO RESPONSE

What type of encephalocele is B?

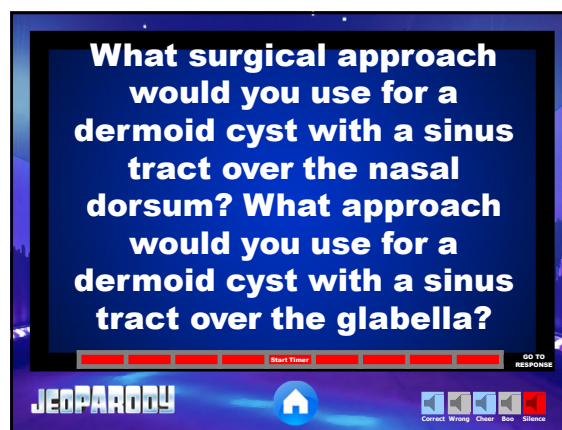
**JEOPARDY!** Start Timer GO TO RESPONSE

Sincipital (aka Nasofrontal ethmoidal), this is Nasofrontal



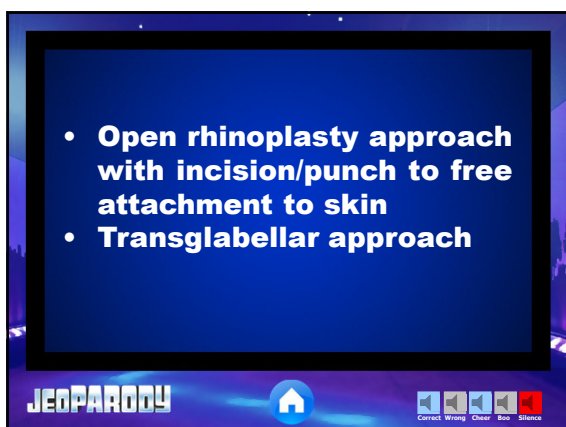
**JEOPARDY!** Start Timer GO TO RESPONSE

What surgical approach would you use for a dermoid cyst with a sinus tract over the nasal dorsum? What approach would you use for a dermoid cyst with a sinus tract over the glabella?



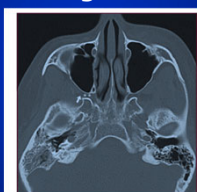
**JEOPARDY!** Start Timer GO TO RESPONSE

- Open rhinoplasty approach with incision/punch to free attachment to skin
- Transglabellar approach

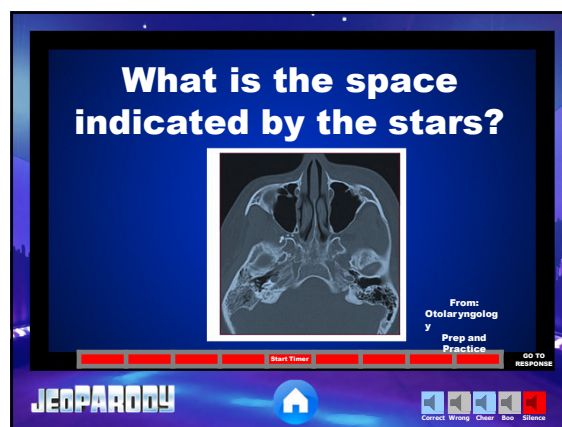


**JEOPARDY!** Start Timer GO TO RESPONSE

What is the space indicated by the stars?



From: Otolaryngology Prep and Practice



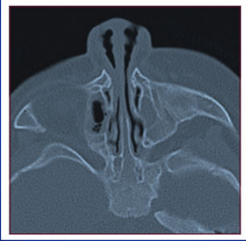
**JEOPARDY!** Start Timer GO TO RESPONSE

**Pterygopalatine fossa**

**JEOPARDY**

Correct Wrong Cheer Boo Silence

Newborn with respiratory distress and feeding difficulties. NGT can't be passed. What diagnosis?



From: Otolaryngology  
Prep and Practice

**JEOPARDY**

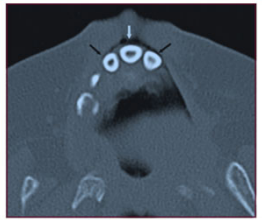
Correct Wrong Cheer Boo Silence

**Piriform aperture stenosis (width <11mm)**

**JEOPARDY**

Correct Wrong Cheer Boo Silence

This finding is found in a patient with piriform aperture stenosis? What else should you look for?



From: Otolaryngology  
Prep and Practice

**JEOPARDY**

Correct Wrong Cheer Boo Silence

Central maxillary mega incisor. Pts with this and piriform aperture stenosis at increased risk for midline abnormalities such as pituitary insufficiency and holoprosencephaly

**JEOPARDY**

Correct Wrong Cheer Boo Silence

Infant with midline external nasal swelling, imaging without intranasal extension. What is the diagnosis?



From: Otolaryngology  
Prep and Practice

**JEOPARDY**

Correct Wrong Cheer Boo Silence



**Nasal Dermoid Cyst**

JEOPARDY! Home Correct Wrong Cheer Boo Silence

**16 yo M w/  
nasal  
obstruction  
and  
epistaxis.  
What is the  
diagnosis?**

Figure 25-5a. H&E stain. 10x.  
Figure 25-5b. H&E stain. 40x.

From:  
Otolaryngology

Prep and  
Practice  
Start Timer

GO TO RESPONSE

JEOPARDY! Home Correct Wrong Cheer Boo Silence

**Juvenile  
nasopharyngeal  
angiofibroma**

JEOPARDY! Home Correct Wrong Cheer Boo Silence

**How is choanal  
atresia  
diagnosed? How  
is the diagnosis  
confirmed?**

Start Timer

GO TO RESPONSE

JEOPARDY! Home Correct Wrong Cheer Boo Silence

**Failure to pass a  
6-10 french  
suction catheter  
Endoscopy to  
confirm**

JEOPARDY! Home Correct Wrong Cheer Boo Silence

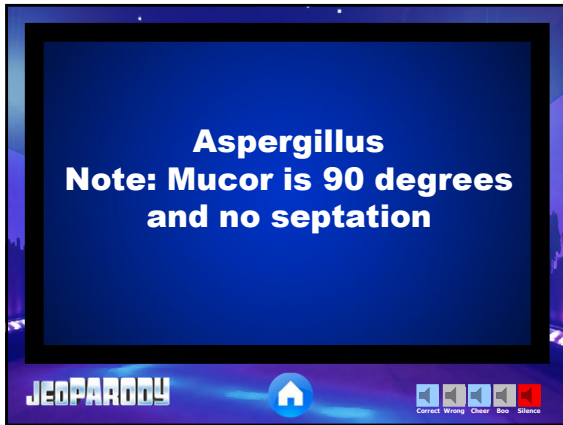
**What fungi has 45 degree  
branching and regular  
septation?**

Start Timer

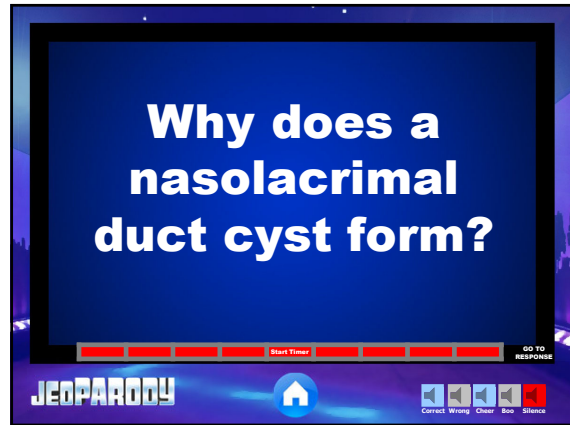
GO TO RESPONSE

JEOPARDY! Home Correct Wrong Cheer Boo Silence

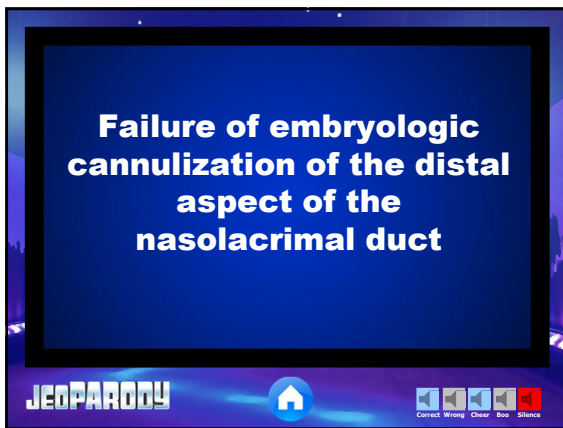
**Aspergillus**  
**Note: Mucor is 90 degrees and no septation**



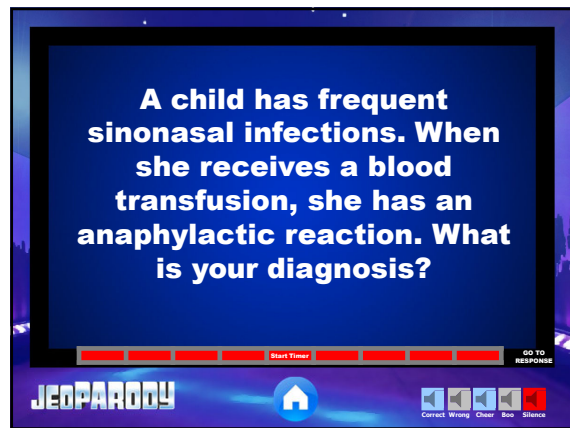
**Why does a nasolacrimal duct cyst form?**



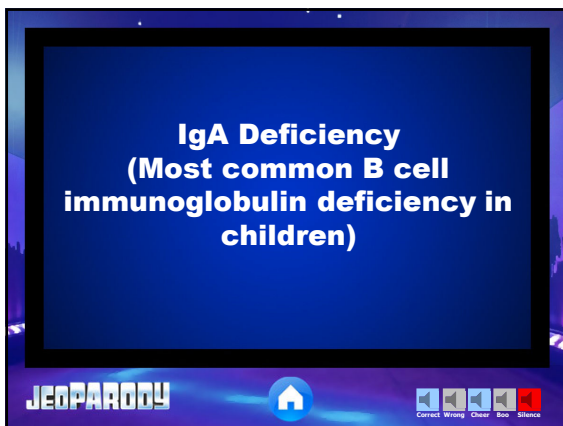
**Failure of embryologic cannulization of the distal aspect of the nasolacrimal duct**



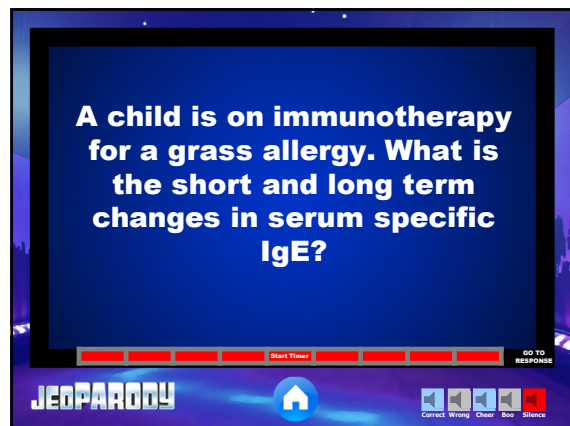
**A child has frequent sinonasal infections. When she receives a blood transfusion, she has an anaphylactic reaction. What is your diagnosis?**









**IgA Deficiency**  
**(Most common B cell immunoglobulin deficiency in children)**



**A child is on immunotherapy for a grass allergy. What is the short and long term changes in serum specific IgE?**



**Short term: increase serum specific IgE**  
**Long term: reduction in serum specific IgE (also increase IgA, increase IgG4)**

**JEPARODY**      

**FINAL JEPARODY**

**JEPARODY**      

**16 yo M w/ nasal obstruction, firm mass in nasal cavity. What is the diagnosis?**

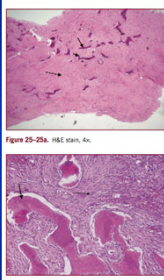









Figure 25-25a: H&E stain, 4x

From: Otolaryngology  
Prep and Practice  
Start Timer  GO TO RESPONSE

**JEPARODY**      

**Fibrous Dysplasia**

**JEPARODY** 